

Evaluation of the safety of epinephrine in digital nerve blockade

Retrospective case series analysis of 1334 toe surgeries

Henry Chapeskie MD CCFP FCFP Alexis Juliao MA Sonja Payne MD MSc FRCA Jennifer Koichopolos

Abstract

Objective To evaluate the safety profile of lidocaine containing 1:200 000 to 1:100 000 epinephrine with concurrent tourniquet use in patients undergoing toe surgery.

Design A retrospective case series analysis of toe procedures performed under digital blockade with adjuvant vasopressor from January 25, 2009, to May 31, 2014, was conducted. Exclusion criteria were limited to procedures performed without adjuvant vasopressor use.

Setting A single clinic in Ontario.

Participants A total of 1334 toe procedures performed in 937 patients.

Main outcome measures The primary study outcome was the incidence of postoperative digital necrosis. Secondary outcomes included other postoperative complications including infection, reperfusion injury, persistent granulation, and damage to the nail matrix.

Results In total, 1334 toe procedures were included in this study, of which 45 involved patients with a pre-existing diagnosis of diabetes mellitus. The overall incidence of postoperative complications was low (4.6%). No cases of digital ischemia or gangrenous necrosis were observed. Subgroup analysis of patients with and without diabetes showed no statistically significant difference in the rate of complications.

Conclusion This study demonstrates the safety of adjuvant vasopressor use in digital nerve blockade of the toes within a large, diverse population. This study adds to a growing base of evidence on the safety of lidocaine with 1:200 000 to 1:100 000 epinephrine for digital anesthesia.

EDITOR'S KEY POINTS

- A myth portraying the dangers of epinephrine use as an adjuvant to digital nerve block exists despite a growing body of contradictory evidence. This myth is founded on 48 cases spanning the past 120 years, many of which occurred more than 50 years ago.
- Out of more than 1300 procedures of adjuvant epinephrine in digital nerve block of the toes reviewed for this study, no cases were complicated with postoperative digital ischemia or necrosis, regardless of diabetes comorbidity. However, use of adjuvant vasoconstrictor in high-risk patients should involve a measured balancing of potential benefits and risks.
- A low incidence of postoperative complications was observed. The most common complication was localized infection. This minor complication is treated conservatively with a short course of oral antibiotics. None of the observed complications are associated with adjuvant vasoconstrictor use.

This article has been peer reviewed.

Can Fam Physician 2016;62:e334-9

Évaluation de l'innocuité de l'épinéphrine dans un bloc nerveux digital

Analyse rétrospective d'une série de 1334 cas de chirurgie de l'orteil

Henry Chapeskie MD CCFP FCFP Alexis Juliao MA Sonja Payne MD MSc FRCA Jennifer Koichopolos

Résumé

Objectif Évaluer le profil d'innocuité de la lidocaïne contenant de l'épinéphrine 1:200 000 à 1:100 000 avec l'utilisation simultanée d'un tourniquet chez des patients ayant subi une chirurgie de l'orteil.

Conception Nous avons effectué une analyse rétrospective d'une série de cas d'interventions à l'orteil exécutées sous bloc digital avec un vasopresseur adjuvant, du 25 janvier 2009 au 31 mai 2014. Les critères d'exclusion se limitaient aux procédures effectuées sans avoir recours à un vasopresseur adjuvant.

Contexte Une seule clinique en Ontario.

Participants Un total de 1334 interventions à l'orteil effectuées chez 937 patients.

Principaux paramètres à l'étude Les principaux paramètres mesurés portaient sur les complications postopératoires, notamment l'infection, la lésion de reperfusion, la granulation persistante et les dommages à la matrice de l'ongle.

POINTS DE REPÈRE DU RÉDACTEUR

- Un mythe persiste entourant les dangers d'utiliser l'épinéphrine comme adjuvant dans un bloc nerveux digital malgré un ensemble grandissant de données démontrant le contraire. Ce mythe se fonde sur 48 cas qui se sont produits sur une période de 120 ans, dont plusieurs remontent à 50 ans.

- Parmi les plus de 1300 interventions examinées pour cette étude impliquant l'épinéphrine adjuvante dans un bloc nerveux digital de l'orteil, il n'y a eu aucun cas d'ischémie ou de nécrose digitale postopératoire comme complication, que le diabète ait été une comorbidité ou non. Toutefois, le recours à un vasoconstricteur chez des patients à risque élevé devrait tenir compte d'un juste équilibre entre les bienfaits et les inconvénients possibles.

- Une faible incidence de complications postopératoires a été observée. La complication la plus fréquente était une infection localisée. Cette complication mineure est traitée de manière conservatrice avec des antibiotiques par voie orale pendant une courte durée. Aucune des complications observées n'était associée à l'utilisation d'un vasoconstricteur adjuvant.

Cet article a fait l'objet d'une révision par des pairs.
Can Fam Physician 2016;62:e334-9

Résultats Au total, 1334 interventions à l'orteil ont été incluses dans cette étude, dont 45 chez des patients ayant reçu antérieurement un diagnostic de diabète. L'incidence globale des complications postopératoires était faible (4,6%). Aucun cas d'ischémie ou de nécrose gangréneuse digitale n'a été observé. Une analyse des sous-groupes de patients diabétiques et sans diabète n'a cerné aucune différence statistiquement significative dans le taux de complications.

Conclusion Cette étude démontre l'innocuité de l'utilisation d'un vasopresseur adjuvant dans le bloc nerveux digital des orteils, et ce, dans une large population diversifiée. Cette étude s'ajoute à un ensemble grandissant de données probantes sur l'innocuité de la lidocaïne avec de l'épinéphrine 1:200 000 à 1:100 000 pour l'anesthésie digitale.

The myth of the danger of epinephrine in digital nerve blocks persists despite growing evidence to the contrary. This long-held tenet has been passed down through generations of physicians and medical literature.¹⁻⁸ The dogma is founded on 48 reported cases in the previous 120 years of digital necrosis following local anesthetic use.⁹ Of these 48 cases, only 21 employed a vasoconstrictor as an adjunct to local anesthesia. This observation suggests other potential confounders exist, such as the use of hot soaks, tight tourniquets, and untreated infections.⁹ Most of these cases occurred more than 50 years ago, when commercially prepared formulations of local anesthetic with vasoconstrictor were not available. It is hypothesized that dilution by hand with inadvertent administration of a higher concentration of epinephrine than currently acceptable (ie, 1:200 000 to 1:100 000) might have contributed to the development of digital ischemia.^{9,10} Of note, all reported cases of digital necrosis used an ester local anesthetic—prilocaine or cocaine, which are each independently implicated in the pathogenesis of tissue necrosis. Substantial differences in preparation, labeling, and storage of drugs before the 1950s led to use of acidic and toxic formulations of prilocaine.¹¹ Cocaine demonstrates potent arterial vasoconstriction and promotes thrombus formation. These pharmacodynamic effects might contribute to development of tissue ischemia.¹²

In recent years, evidence has accrued regarding the safety of epinephrine in digital hand surgery.^{3,6,13} In these studies combined, more than 5000 participants received epinephrine in conjunction with a local anesthetic to achieve regional anesthesia of the hand or finger. No gangrenous necrosis was reported. The introduction of phentolamine, an α -adrenergic antagonist, as an antidote for vasoconstrictor-mediated digital ischemia has further reduced the risk of using epinephrine in digital surgery.^{14,15}

The use of epinephrine-containing anesthetics for digital blockade of the toes has been studied less extensively. Historically, case studies exceeding 200 000 in total used epinephrine as an adjuvant to regional anesthesia for foot surgery without gangrenous complications.^{16,17} However, these procedures involved regional blocks throughout the foot and were not specific to digital toe surgery. More recently Altinyazar et al performed a small randomized controlled trial evaluating the safety profile of epinephrine in digital blockade of the toe.² Results demonstrated no difference in postoperative complications between the study groups. Despite limitations to this study (ie, small sample size and strict exclusion criteria), it provides a foundation for evaluation of vasoconstrictor use in regional toe blockade. Research in digital blockade of the toe has excluded patients with pre-existing peripheral vascular disease and diabetes mellitus.² Extrapolation of results to these groups might

not be appropriate and caution is advised in the use of vasoconstrictor in digital blockade for such patients.

The purpose of this retrospective study was to evaluate the safety profile of lidocaine with 1:200 000 to 1:100 000 epinephrine with concurrent tourniquet use in patients undergoing toe surgery.

METHODS

This single-centre retrospective case series was approved by the Western University Research Ethics Board. All records of patients undergoing surgical procedures of the toe involving digital blockade with adjuvant vasoconstrictor were identified using an electronic database of surgical procedures performed between January 25, 2009, and May 31, 2014.

The following data were collected: age, comorbid diabetes diagnosis, procedure performed, number of toes anesthetized, type of anesthesia used, and postoperative complications. Data collection was conducted by 2 independent investigators (A.J. and J.K.).

The principal investigator (H.C.) managed each patient encounter including preoperative consultation, surgery, and postoperative care. Postoperative complications were followed by H.C. through in-clinic visits or via e-mail, with all data recorded in the associated medical records. The primary study outcome was the incidence of postoperative digital necrosis. Secondary outcomes included postoperative complications, including infection, reperfusion injury, persistent granulation, damage to the nail matrix, or other. Exclusion criteria were limited to the use of local anesthesia without adjuvant vasoconstrictor.

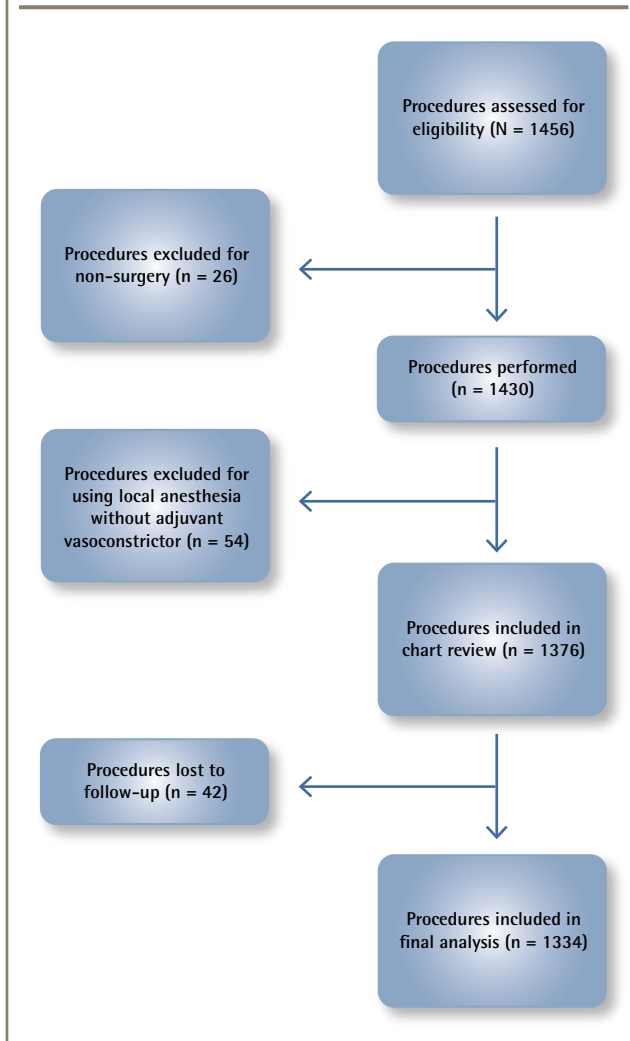
Statistical analysis was performed using Minitab 17. Descriptive data are presented as numbers and proportions. Differences in categorical postoperative outcomes were analyzed using the Fisher exact test. A *P* value less than .05 was considered statistically significant.

RESULTS

Figure 1 shows the study flow diagram. A total of 1430 digital toe procedures were performed during the study period. Of these cases eligible for inclusion, 1334 procedures performed in 937 patients were included in the final analysis. Of the cases excluded from analysis, 26 participants had declined surgery following preoperative consultation. Fifty-four surgical procedures were performed under local anesthesia without adjuvant vasoconstrictor and were therefore excluded from analysis.

Patient demographic characteristics

Approximately half of the procedures were performed for

Figure 1. Selection of procedures for inclusion in analysis

patients aged 19 to 64 years. Less than 4% of procedures were performed for patients with a pre-existing diagnosis of diabetes mellitus. Patient demographic characteristics are summarized in **Table 1**.

Procedure and anesthetic

Nail fold skin excision accounted for 90.6% of performed procedures. Epinephrine concentration of 1:100 000 was used in 87.3% of all procedures. A digital tourniquet was used for all procedures.

Postoperative complications

Complications are summarized in **Table 2**. A total of 4.6% of all procedures developed a postoperative complication. No cases of ischemia or gangrenous necrosis were observed. The most common postoperative complication was infection, with localized infection of the toe accounting for 63.9% of total complications. Only a single case demonstrated extension of infection requiring

treatment with intravenous antibiotics. There was no statistically significant difference in the rate of complications between patients with diabetes and those without. Subanalysis of postoperative complications and vasoconstrictor concentration did not demonstrate a statistically significant difference (**Table 3**).

DISCUSSION

The use of epinephrine as an adjuvant to lidocaine anesthetic has several clinical advantages related to its vasoconstrictive effects. The provision of a bloodless operative field is of primary importance to the surgeon performing digital surgery. In addition, research has demonstrated that addition of epinephrine to local anesthetics statistically significantly shortens the time to onset of anesthesia, reduces the anesthetic dose required to achieve anesthesia, and prolongs anesthetic duration of action.^{11,18-20}

Physiologic effects of epinephrine injection in the digits have been studied extensively. Sylaidis and Logan observed the maintenance of digital arterial lumen patency following digital nerve blocks containing 1:80 000 epinephrine.⁷ Sönmez et al demonstrated no difference in fingertip capillary blood gases in digits anesthetized with lidocaine and epinephrine compared with lidocaine alone. This finding suggests sufficient perfusion of the digit is maintained with 1:80 000 epinephrine.¹⁹ Doppler evaluation of the effects of epinephrine on digital artery flow of fingers and toes of healthy volunteers demonstrated an expected temporary reduction in arterial blood flow velocity resulting in a reversible low-flow, but not no-flow, state.¹ Reduction in end-artery flow might be theoretically exacerbated in patients with pre-existing vaso-occlusive or vasospastic disease, predisposing to a no-flow state. This physiologic extrapolation merits careful patient selection when using adjuvant vasoconstrictors for digital nerve blockade. Many studies exclude patients with known peripheral vascular disease or vasospastic disorders, and experts still recommend caution in these patient groups.^{21,22}

The practice of digital nerve blockade within this study is the product of careful preprocedural patient selection. Owing to the theoretical risk of digital ischemia in high-risk patients, adjuvant vasoconstrictor was not used in patients with a poorly palpable peripheral pulse or known Raynaud syndrome; these exclusion criteria accounted for more than half of the procedures performed without adjuvant vasoconstrictor during the study period. Other indications for anesthesia without vasoconstriction included minor procedures with minimal bleeding (ie, minor cautery and curettage) or previous history of adverse effects of vasoconstrictor use. Within this subset of 54 procedures, there were no cases

Table 1. Patient and procedural characteristics

CHARACTERISTIC	NO DIABETES COMORBIDITY (N = 1289), N (%)	DIABETES COMORBIDITY (N = 45), N (%)	TOTAL (N = 1334), N (%)
Age, y			
• ≤ 12	101 (7.8)	2 (4.4)	103 (7.7)
• 13-18	470 (36.5)	2 (4.4)	472 (35.4)
• 19-64	667 (51.7)	30 (66.7)	697 (52.2)
• > 64	51 (4.0)	11 (24.4)	62 (4.6)
Procedure			
• Nail fold skin excision	1172 (90.9)	36 (80.0)	1208 (90.6)
• Partial nail avulsion	50 (3.9)	4 (8.9)	54 (4.0)
• Complete nail avulsion	57 (4.4)	5 (11.1)	62 (4.6)
• Cautery and curettage	10 (0.8)	0 (0.0)	10 (0.7)
Vasopressor concentration			
• Epinephrine 1:100 000	1127 (87.4)	38 (84.4)	1165 (87.3)
• Epinephrine 1:200 000	162 (12.6)	7 (15.6)	169 (12.7)

Table 2. Postoperative complications

COMPLICATION	NO DIABETES COMORBIDITY (N = 1289), N (%)	DIABETES COMORBIDITY (N = 45), N (%)	P VALUE
Total	59 (4.6)	2 (4.4)	.661
Digital necrosis or ischemia	0 (0.0)	0 (0.0)	NA
Infection			
• Localized to toe	38 (2.9)	1 (2.2)	.618
• Extension to foot	1 (0.1)	0 (0.0)	.966
Persistent granulation	9 (0.7)	0 (0.0)	.734
Reperfusion injury	7 (0.5)	0 (0.0)	.786
Neuropathy	3 (0.2)	1 (2.2)	.128
Onychomycosis	1 (0.1)	0 (0.0)	.966

NA—not applicable.

of digital ischemia. The incidence of postoperative complications was less than 4%, with only 2 cases of localized infection observed.

Clinical exclusion criteria for the use of adjuvant epinephrine did not strictly include a comorbid diagnosis of diabetes. This patient subgroup has attracted specific concern in the use of digital vasoconstrictor owing to the prevalence of peripheral vascular disease.^{2,3,16,19,20,23} In our case series of more than 1300 procedures of adjuvant epinephrine in digital nerve block of the toes, no cases were complicated with postoperative digital ischemia or necrosis, regardless of diabetes comorbidity. This finding is consistent with results from a previous retrospective study by Firoz et al evaluating the safety profile of epinephrine in digital surgery.²⁴ In this case study, patients with established peripheral vascular disease or associated risk factors were included in the analysis. More than 60% of patients had a diagnosis of hypertension and approximately one-third had a history

Table 3. Vasoconstrictor concentrations and postoperative complications

VASOPRESSOR CONCENTRATION	POSTOPERATIVE COMPLICATIONS,* N (%)	TOTAL PROCEDURES
Epinephrine 1:100 000	58 (5.0)	1165
Epinephrine 1:200 000	3 (1.8)	169

*P=.074.

of diabetes or circulatory disorder. Despite study limitations due to sample size (N=63), the researchers did not observe any cases of digital ischemia or gangrene.²⁴ Our results support these observations and suggest that comorbid vascular risk factors are not an absolute contraindication for the use of epinephrine in digital nerve blockade. However, use of adjuvant vasoconstrictor in high-risk patients should involve a measured balancing

of proposed benefits and risks. Where risks outweigh the benefits (eg, clinical signs of vascular compromise, minor procedure with minimal bleeding or postoperative pain), vasoconstrictor should be omitted.

We observed a low incidence of postoperative complications. The most common complication was localized infection. This minor complication is treated conservatively with a short course of oral antibiotics. None of the observed complications are associated with adjuvant vasoconstrictor use.

Most procedures in our case series were performed using a 1:100 000 concentration of epinephrine. The complication rate in this group exceeded the rate in patients receiving 1:200 000 adjuvant epinephrine, although this difference was not statistically significant. To our knowledge, the physiologic differences in digital end-artery flow secondary to different concentrations of vasoconstrictors have not been studied.

Limitations

The retrospective nature of our study relies on the quality of information documented in the medical records. Nearly 3% of total procedures performed during the study period were lost to follow-up. It is our practice to maintain close clinical follow-up in the early postoperative period, either through clinical attendance or via video or voice calls. As digital ischemia occurs early within the postoperative period, it is unlikely any cases occurred without our knowledge. However, other postoperative complications might have been reported elsewhere.

Conclusion

This case series supports the growing evidence of the safety of adjuvant vasoconstrictor use in digital nerve blockade. In addition, patients with a comorbid diagnosis of diabetes mellitus, a known risk factor for peripheral vascular disease, does not preclude digital vasoconstrictor use.

Dr Chapeskie is a medical practitioner at the Thorndale Lions Medical Centre in Thorndale, Ont, and Adjunct Professor in the Department of Family Medicine at Western University in London, Ont. **Ms Juliao** is a midwifery student at McMaster University in Hamilton, Ont. **Dr Payne** is a specialty trainee in anesthetics at the Bristol School of Anaesthesia in the United Kingdom. **Ms Koichopolos** is a medical student at Western University.

Contributors

Dr Chapeskie and **Ms Juliao** were responsible for the conception and design of the study. Study data were acquired by **Dr Chapeskie** and **Ms Juliao**. **Ms Juliao** and **Ms Koichopolos** collected the study data. All authors contributed to the analysis and interpretation of the study data. **Dr Payne** and **Ms Koichopolos**

drafted the article, and **Dr Chapeskie**, **Ms Juliao**, and **Dr Payne** provided critical revisions for important intellectual content. All authors gave final approval of the version to be published and agreed to act as guarantors of the work.

Competing interests

None declared

Correspondence

Dr Henry Chapeskie; e-mail henry.chapeskie@gmail.com

References

- Altinyazar HC, Ozdemir H, Koca R, Hoşnuter M, Demirel CB, Gündoğdu S. Epinephrine in digital block: color Doppler flow imaging. *Dermatol Surg* 2004;30(4 Pt 1):508-11.
- Altinyazar HC, Demirel CB, Koca R, Hoşnuter M. Digital block with and without epinephrine during chemical matricectomy with phenol. *Dermatol Surg* 2010;36(10):1568-71.
- Chowdhry S, Seidenstricker L, Cooney DS, Hazani R, Wilhelmi BJ. Do not use epinephrine in digital blocks: myth or truth? Part II. A retrospective review of 1111 cases. *Plast Reconstr Surg* 2010;126(6):2031-4.
- Harness NG. Digital block anesthesia. *J Hand Surg Am* 2009;34(1):142-5.
- Krunic AL, Wang LC, Soltani K, Weitzul S, Taylor RS. Digital anesthesia with epinephrine: an old myth revisited. *J Am Acad Dermatol* 2004;51(5):755-9.
- Lalonde D, Bell M, Benoit P, Sparkes G, Denkler K, Chang P. A multicenter prospective study of 3,110 consecutive cases of elective epinephrine use in the fingers and hand: the Dalhousie Project clinical phase. *J Hand Surg Am* 2005;30(5):1061-7.
- Sylaidis P, Logan A. Digital blocks with adrenaline. An old dogma refuted. *J Hand Surg Br* 1998;23(1):17-9.
- Waterbrook AL, Germann CA, Southall JC. Is epinephrine harmful when used with anesthetics for digital nerve blocks? *Ann Emerg Med* 2007;50(4):472-5.
- Denkler K. A comprehensive review of epinephrine in the finger: to do or not to do. *Plast Reconstr Surg* 2001;108(1):114-24.
- Mohan PP. Epinephrine in digital nerve block. *Emerg Med J* 2007;24(11):789-90.
- Thomson CJ, Lalonde DH. Randomized double-blind comparison of duration of anesthesia among three commonly used agents in digital nerve block. *Plast Reconstr Surg* 2006;118(2):429-32.
- Dhawan SS, Wang BW. Four-extremity gangrene associated with crack cocaine abuse. *Ann Emerg Med* 2007;49(2):186-9. Epub 2006 Oct 23.
- Wilhelmi BJ, Blackwell SJ, Miller JH, Mancoll JS, Dardano T, Tran A, et al. Do not use epinephrine in digital blocks: myth or truth? *Plast Reconstr Surg* 2001;107(2):393-7.
- Nodwell T, Lalonde D. How long does it take phentolamine to reverse adrenaline-induced vasoconstriction in the finger and hand? A prospective, randomized, double-blinded study: the Dalhousie Project experimental phase. *Can J Plast Surg* 2003;11(4):187-90.
- Molony D. Adrenaline-induced digital ischaemia reversed with phentolamine. *ANZ J Surg* 2006;76(12):1125-6.
- Steinberg MD, Block PB. The use and abuse of epinephrine in local anesthetics. *J Am Podiatry Assoc* 1971;61(9):341-3.
- Radovic P, Smith RG, Shumway D. Revisiting epinephrine in foot surgery. *J Am Podiatr Med Assoc* 2003;93(2):157-60.
- Andrades PR, Olguin FA, Calderón W. Digital blocks with or without epinephrine. *Plast Reconstr Surg* 2003;111(5):1769-70.
- Sönmez A, Yaman M, Ersoy B, Numanodlu A. Digital blocks with and without adrenalin: a randomised-controlled study of capillary blood parameters. *J Hand Surg Eur Vol* 2008;33(4):515-8.
- Calder K, Chung B, O'Brien C, Lalonde DH. Bupivacaine digital blocks: how long is the pain relief and temperature elevation? *Plast Reconstr Surg* 2013;131(5):1098-104.
- Lalonde DH, Lalonde JF. Discussion. Do not use epinephrine in digital blocks: myth or truth? Part II. A retrospective review of 1111 cases. *Plast Reconstr Surg* 2010;126(6):2035-6.
- Lee J, Crane S. Lidocaine with epinephrine for digital nerve blocks: a note of caution [Letter]. *Emerg Med J* 2010;27(4):335.
- Wilhelmi BJ, Blackwell SJ, Miller J, Mancoll JS, Phillips LG. Epinephrine in digital blocks: revisited. *Ann Plast Surg* 1998;41(4):410-4.
- Firoz B, Davis N, Goldberg LH. Local anesthesia using buffered 0.5% lidocaine with 1:200,000 epinephrine for tumors of the digits treated with Mohs micrographic surgery. *J Am Acad Dermatol* 2009;61(4):639-43.

— * * * —