On Emerging Technology: What to Know When Your Patient Has a Microchip in His Hand

Brianna R. Fram, MD,*† Michael Rivlin, MD,*† Pedro K. Beredjiklian, MD*†

Radio-frequency identification (RFID) technology uses an antenna to respond to an incoming signal by sending an outgoing message. This technology has been in use for over 50 years and is common in daily activities such as tapping a credit card to a reader, swiping an ID badge to open a door, paying highway tolls, and operating keyless entry cars. This technology can be implanted, such as in the microchips used to identify domestic pets. Since 1998, RFID chips have also been implanted in humans. This practice is little studied but appears to be increasing; rice-sized implants are implanted by hobbyists and even offered by some employers for uses ranging from access to emergency medical records to entry to secured workstations. These implants are of special concern to hand surgeons because they are most commonly placed in the subcutaneous dorsal first web space. The US Food and Drug Administration first approved this technology in 2004, with stated potential risks including adverse tissue reaction, migration of the implanted transponder, compromise of information security, electrical hazards, and magnetic resonance imaging incompatibility. Here, we explain implanted RFID technology, its potential uses, and what is and is not known about its safety. We present images of a patient with an RFID chip who presented to our clinic for acute metacarpal and phalangeal fractures, to demonstrate the clinical and radiographic appearance of these chips. *(J Hand Surg Am. 2020;■(■):■−■. Copyright © 2020 by the American Society for Surgery of the Hand. All rights reserved.)*

Key words Hand microchip, microchip implant, MRI safety, radiofrequency identification, RFID.

RADIO-FREQUENCY IDENTIFICATION (RFID) technology has been in use for over 50 years. The technology involves a microchip attached to an antenna, which responds to an incoming signal from a reader by sending an outgoing signal. Most chips do not have an energy source and do this passively, signaling only when they receive an incoming query of the appropriate frequency.[1] First pioneered during World War II, the use of this technology has become commonplace in daily activities such as tapping a credit card to a reader, swiping an ID badge to open a door, paying highway tolls, and operating keyless entry cars.[2] The technology is increasingly being used for health care applications including monitoring hand hygiene compliance, tracking medical equipment, identifying retained surgical instruments, and tracking and labeling valuable drugs and biological samples.[3–5]

Although implanted RFID chips have been used for several decades in veterinary medicine to track and identify household pets and livestock, human

*From the *Department of Orthopaedic Surgery, Thomas Jefferson University; and the †Rothman Institute of Orthopedics, Philadelphia, PA*

Received for publication June 22, 2019; accepted in revised form January 15, 2020.

No benefits in any form have been received or will be received related directly or indirectly to the subject of this article.

Corresponding author: Brianna R. Fram, MD, Department of Orthopaedic Surgery, Thomas Jefferson University, 925 Chestnut Street, 5th Floor, Philadelphia, PA 19107; e-mail: Brianna.Fram@rothmanortho.com.

0363-5023/20/■ ■-0001$36.00/0
https://doi.org/10.1016/j.jhsa.2020.01.008

implantation of these devices has not been routinely studied.[1] Despite the lack of knowledge regarding the safety profiles of these implants, RFID chips are increasingly being implanted in humans. The first reported RFID implanted into a human was done in 1998 on Professor Kevin Warwick, now of Coventry University. The US Food and Drug Administration wrote an industry guidance document on implantable RFID devices in 2004 and first approved the use of this technology that same year in the form of the VeriChip system (VeriChip Corporation, Delray Beach, FL), with stated potential risks of adverse tissue reaction, migration of the implanted transponder, compromise of information security, failure of the implanted transponder or its inserter or scanner, electromagnetic interference, electrical hazards, and magnetic resonance imaging (MRI) incompatibility.[6] Although VeriChip stopped producing the chips in 2010, implantable chips remain available for purchase online through companies such as Dangerous Things, whose site contains a disclaimer that the implants they sell have "not been certified by any government regulatory agency for implantation or use inside the human body."[7,8]

The microchips, which are the size of a grain of rice, are designed to be placed using a large injecting syringe, most often in the subcutaneous tissues over the dorsal first web space or over the posterior triceps.[7] Whereas most receiving these implanted devices are hobbyists and so-called biohackers, several employers and even the Mexican government have offered the implants to employees.[9,10] The increase in implantation has received broad press coverage, and although there are no clear figures, the Swedish company BioHax (BioHax International, Helsingborg, Sweden) claims nearly 4,000 customers with RFID implants and US-based Dangerous Things reports over 10,000 chips sold.[11,12] Reported uses of RFID chips in humans include access to medical and vaccination records, identification of patients with mental status changes, no-touch payment, and entry to secured doors and workstations.[10,11]

THE POTENTIAL ISSUES

Local tissue concerns

Most reports online detail nonmedical personnel, such as piercing professionals or hobbyists, introducing these devices into one another outside a health care setting, which raises concern about the sterility of insertion and awareness of known underlying anatomic structures.[13] Published literature on animals has limited reports of adverse events. These RFID chips are most commonly placed subcutaneously, such as between the scapulae in cats and dogs, but also submuscularly in animals such as birds. There are case reports of microchip-associated fibrosarcoma in cats, dogs, rodents and an Egyptian fruit bat (Albrecht, presented at the 2010 IEEE International Symposium on Technology and Society).[14–18] There is also one reported case of spinal cord injury developing acutely after microchip placement in a cat, in which the chip was found compressing the spinal canal and had to be surgically removed.[19] The RFID microchips have also been implanted in birds and amphibians with few reported complications.[20,21] There is scarce evidence on the safety of implanted microchips in humans in the peer-reviewed literature. A publication on the use of RFID chips to localize breast lesions for surgical biopsy reported successful results and no complications such as migration.[22]

Compromise of information security

Use of RFID chips containing personal information may put participants at risk for theft. As early as 2006, *Wired* magazine[23] published an article on the ease of hacking information from an RFID door key card, RFID tracking devices within library books, and even an encrypted VeriChip implanted in a human upper arm. Furthermore, in some cases the hackers were able to write new information or edit existing information on the chips. The potential for hacking of RFID chips containing protected health information is of particular concern.

Failure of implanted transponder or its scanner

There are no human data on the failure rates of implanted RFID chips. In the veterinary literature, in a population of 538 microchipped domestic cats, 99.8% of implanted RFIDs were still functional 6 months after placement.[24] However when using the chips as ID devices, such as in lost animals, there is ongoing concern in the veterinary field that not all chips used in the United States emit the same frequency, and that even universal scanners tend to have sensitivities at only about 95% for detecting the RFID chips, and even lower for lower-frequency (125-kHz) chips.[25] The US government and health care providers should be cognizant of this if the medical use of these chips increases, because it could create difficulty with using this technology to carry patient medical history or legal representative contact information.

Electromagnetic and electrical interference

There are no data in the human or veterinary literature on the safety of using monopolar or bipolar electrocautery devices in proximity to these implants. This

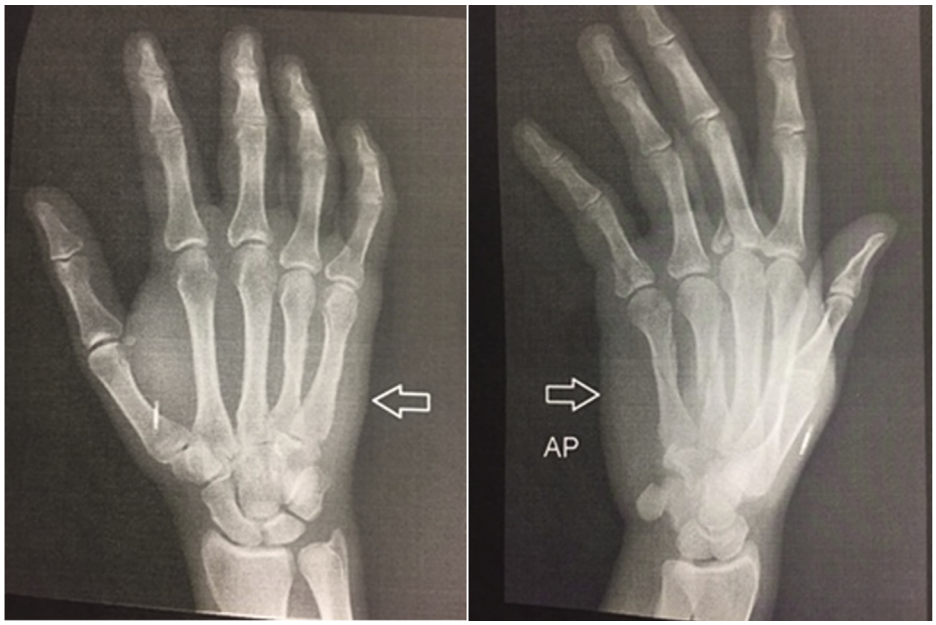

FIGURE 1: Radiographs of a patient recently seen in our hand clinic with fourth and fifth metacarpal and middle and little finger proximal phalanx fractures who had implanted an RFID chip into the hand. He reported using the chip to unlock his front door and drive his keyless entry car. He underwent operative fixation of the fractures without incidence. Electrocautery was not used during his case.

FIGURE 2: Clinical radiographs of the patient from Figure 1 during routine follow-up. The RFID chip can be seen in the subcutaneous tissue overlying the dorsal first web space. It was easily palpable and moderately mobile on examination.

could theoretically lead to increased fire risk, cauterization of unintended structures, or damage to the microchip. There is variability in the composition of microchips, although the commercially available ones typically contain a ferrite coil encased in biocompatible glass with or without a polymer coating to prevent chip migration.[1] Regarding MRI safety, researchers have tested common brands of veterinary RFID chips in up to 3T scanners. They found that measurable translation and torque of the chips occurred and the chips generated artifact that could interfere with imaging of nearby structures, but that the scanners did not cause notable heating or affect microchip function.[26–28] Multiple authors also tested externally worn patient ID tags containing RFID chips in humans using MRI scanners ranging from 0.3 to 3T. The devices continued to function without data loss after MRI and did not show major heating or movement, but increasing the magnetic field strength caused impairment in assessing nearby structures such as nerves and tendons.[29–32] Similar studies on external RFID devices in computed tomography scanners have shown low levels of artifact and no alterations in chip function.[29,30] However, most authors still recommend monitoring patients continuously during examination and using caution when performing MRI in the sedated patient with an implant.

WHAT THE HAND SURGEON NEEDS TO KNOW

The presence of microchip implants in patients' hands raises several concerns for hand surgeons in particular. Overall, the hand surgeon should be aware

that these devices exist and ought to be cognizant of the impact they may have on diagnostic workup and surgical intervention. Hand surgeons should be familiar with the appearance of RFID chips radiographically (Fig. 1) and clinically (Fig. 2), especially in the setting of an obtunded or noncommunicative patient. In the obtunded trauma patient, these chips could be confused with a retained foreign body in the setting of soft tissue defects, leading to unnecessary surgical intervention. Any signs of fullness or erythema over an implanted RFID chip should raise concern for infection or development of malignancy and prompt a workup and possibly discussion of implant removal. Magnetic resonance imaging is likely safe in the awake cooperative patient with an implanted RFID, but in the obtunded patient there are insufficient data and it may be relatively contraindicated. Magnetic resonance imaging sensitivity may be decreased for tissues in the vicinity of an implanted RFID chip, and therefore imaging modalities such as ultrasound or computed tomography may be preferable in specific situations with pathology adjacent to a chip. Implants may interfere with intraoperative fluoroscopic imaging, increase the risk for infection, or simply be a liability that could be damaged during surgery. The possibility of implant damage should be discussed with patients before surgery and documented. It is also unclear how electrocautery will interact with RFID chips, and it should be used with caution around them. These implants are increasingly prevalent and hand surgeons should be aware of their existence and potential pitfalls.

CONCLUSION

In the face of this emerging technology, it is essential that hand surgeons recognize the nuances of treating patients who have implanted RFID chips and also the promise and risk of this technology within the field of health care. As human reliance on technology increases and the desire to interface seamlessly with the systems around us grows, the likelihood is that many hand surgeons will treat a patient with an RFID chip or other implanted technology in the hand in the future.

REFERENCES

1. Troyk PR. Injectable electronic identification, monitoring, and stimulation systems. *Annu Rev Biomed Eng*. 1999;1(1):177−209.
2. Fosso Wamba S, Anand A, Carter L. A literature review of RFID-enabled healthcare applications and issues. *Int J Inf Manage*. 2013;33(5):875−891.
3. SwipeSense. Available at: https://www.swipesense.com/. Accessed May 30, 2019.
4. Safdari R, Maserat E. RFID technology in health environment: opportunities and challenges for modern cancer care. *Asian Pac J Cancer Prev*. 2012;13(12):6533−6537.
5. Yao W, Chu C, Li Z. The adoption and implementation of RFID technologies in healthcare: a literature review. *J Med Syst*. 2012;36(6):3507−3525.
6. US Food and Drug Administration, Health and Human Services. Medical devices; general hospital and personal use devices; classification of implantable radiofrequency transponder system for patient identification and health information. final rule. *Fed Regist*. 2004;69(237):71702−71704.
7. RFID & NFC human chip implants−biohacking. Available at: https://dangerousthings.com/. Accessed June 22, 2019.
8. Chip implanter PositiveID aims to clean up a PR mess—one of its own making. Available at: https://www.cbsnews.com/news/chip-implanter-positiveid-aims-to-clean-up-a-pr-mess-one-of-its-own-making/. Accessed June 22, 2019.
9. Weissert W. Microchips implanted in Mexican officials. Available at: http://www.nbcnews.com/id/5439055/ns/technology_and_science-tech_and_gadgets/t/microchips-implanted-mexican-officials/. Accessed June 14, 2019.
10. Astor M. Microchip implants for employees? One company says yes. Available at: https://www.nytimes.com/2017/07/25/technology/microchips-wisconsin-company-employees.html. Accessed June 8, 2019.
11. Graham J. You will get chipped—eventually. Available at: https://www.usatoday.com/story/tech/2017/08/09/you-get-chipped-eventually/547336001/. Accessed June 22, 2019.
12. Walt V. Is "biochipping" a good idea?. Available at: http://fortune.com/longform/biochipping-biohax-microchip/. Accessed June 22, 2019.
13. Eveleth R. Why did I implant a chip in my hand?. Available at: https://www.popsci.com/my-boring-cyborg-implant/. Accessed June 22, 2019.
14. Elcock LE, Stuart BP, Wahle BS, et al. Tumors in long-term rat studies associated with microchip animal identification devices. *Exp Toxicol Pathol*. 2001;52(6):483−491.
15. Blanchard KT, Barthel C, French JE, et al. Transponder-induced sarcoma in the heterozygous p53+/- mouse. *Toxicol Pathol*. 1999;27(5):519−527.
16. Schutt LK, Turner PV. Microchip-associated sarcoma in a shrew (Suncus murinus). *J Am Assoc Lab Anim Sci*. 2010;49(5):638−641.
17. Siegal-Willott J, Heard D, Sliess N, Naydan D, Roberts J. Microchip-associated leiomyosarcoma in an Egyptian fruit bat (Rousettus aegyptiacus). *J Zoo Wildl Med*. 2007;38(2):352−356.
18. Vascellari M, Melchiotti E, Mutinelli F. Fibrosarcoma with typical features of postinjection sarcoma at site of microchip implant in a dog: histologic and immunohistochemical study. *Vet Pathol*. 2006;43(4):545−548.
19. Platt S, Wieczorek L, Dennis R, De Stefani A. Spinal cord injury resulting from incorrect microchip placement in a cat. *J Feline Med Surg*. 2007;9(2):157−160.
20. Granzow E. Microchip placement for identification of birds. *Lab Anim (NY)*. 2008;37(1):21−22.
21. Mrozek M, Fischer R, Trendelenburg M, Zillmann U. Microchip implant system used for animal identification in laboratory rabbits, guineapigs, woodchucks and in amphibians. *Lab Anim*. 1995;29(3):339−344.
22. Dauphine C, Reicher JJ, Reicher MA, Gondusky C, Khalkhali I, Kim M. A prospective clinical study to evaluate the safety and performance of wireless localization of nonpalpable breast lesions using radiofrequency identification technology. *AJR Am J Roentgenol*. 2015;204(6):W720−W723.
23. Newitz A. The RFID hacking underground. Available at: https://www.wired.com/2006/05/rfid-2/. Accessed February 6, 2019.

24. Lord LK, Griffin B, Slater MR, Levy JK. Evaluation of collars and microchips for visual and permanent identification of pet cats. *J Am Vet Med Assoc*. 2010;237(4):387−394.
25. Lord LK, Pennell ML, Ingwersen W, Fisher RA, Workman JD. In vitro sensitivity of commercial scanners to microchips of various frequencies. *J Am Vet Med Assoc*. 2008;233(11):1723−1728.
26. Piesnack S, Frame ME, Oechtering G, Ludewig E. Functionality of veterinary identification microchips following low- (0.5 tesla) and high-field (3 tesla) magnetic resonance imaging. *Vet Radiol Ultrasound*. 2013;54(6):618−622.
27. Haifley KA, Hecht S. Functionality of implanted microchips following magnetic resonance imaging. *J Am Vet Med Assoc*. 2012;240(5):577−579.
28. Saito M, Ono S, Kayanuma H, Honnami M, Muto M, Une Y. Evaluation of the susceptibility artifacts and tissue injury caused by implanted microchips in dogs on 1.5 T magnetic resonance imaging. *J Vet Med Sci*. 2010;72(5):575−581.
29. Periyasamy M, Dhanasekaran R. Assessment of safety and interference issues of radio frequency identification devices in 0.3 tesla magnetic resonance imaging and computed tomography. Available at: https://www.hindawi.com/journals/tswj/2014/735762/. Accessed June 22, 2019.
30. Steffen T, Luechinger R, Wildermuth S, et al. Safety and reliability of radio frequency identification devices in magnetic resonance imaging and computed tomography. *Patient Saf Surg*. 2010;4(1):2.
31. Cheng C, Chai J. Deployment of RFID in healthcare facilities—experimental design in MRI department. *J Med Syst*. 2012;36(6):3423−3433.
32. Titterington B, Shellock FG. Evaluation of MRI issues for an access port with a radiofrequency identification (RFID) tag. *Magn Reson Imaging*. 2013;31(8):1439−1444.